

TxD

Z US905.6 ON1 53:03

A Publication of

M. D. Anderson
Cancer Center

Making Cancer History®

5

In Brief

Drug tested for lymphoma relapse prevention, and more

7

House Call

Understanding the different types of biopsies



8

DiaLog

Genome project could unlock secrets of cancer biology

Texas State Documents
Collection

REPORT TO PHYSICIANS

MARCH 2008 VOL. 53, NO. 3

Oncology

In Search of the Answer


Modern medicine is chipping away at the mystery of unknown primary tumors.

By John LeBas

The advent of hormonal therapies, protein inhibitors, and other drugs that attack specific cancer types has brought new hope to patients with metastatic disease. By acting against the biologic pathways that enable tumors to grow and proliferate, these targeted therapies are extending the survival of late-stage cancer patients.

But for some, the promise of targeted therapies can be frustratingly out of reach. That's because these drugs are most effective when selected for a specific disease type—which isn't always possible when a patient has the mysterious and puzzling disease presentation known as cancer of unknown primary origin (CUP).

NON-CIRCULATING
U of NT



Dr. Gauri Varadhachary and Dr. Martin Raber are working to better individualize treatment for patients with cancer of unknown primary origin.

CUP often carries a grim outlook. It's bad enough that the disease has already spread by the time of diagnosis, since metastatic cancer is notoriously difficult to treat. Even worse, CUP patients and their doctors can never be certain what kind of cancer they're dealing with, so the choice of effective therapy is at best an educated
(Continued on page 2)

THE UNIVERSITY OF TEXAS
MD ANDERSON
CANCER CENTER

U of NT Dep. Libraries
76203

08-500
Rec'd June 3, 2008

In Search of the Answer

(Continued from page 1)

guess. Fewer than 25% of CUP patients remain alive after 1 year.

"It's a diagnosis that patients are, understandably, uneasy about. It's a diagnosis that their doctors are uneasy about. And that's why we see so many patients with it here at M. D. Anderson," said Martin Raber, M.D., a professor of gastrointestinal medical oncology at The University of Texas M. D. Anderson Cancer Center, which treats about 300 CUP patients each year.

However, Dr. Raber and other clinicians are slowly taking the guesswork out of CUP therapy, thanks to high-quality imaging, advanced pathology and immunohistochemistry techniques, and the evolving science of genetic profiling. Today, CUP patients have a greater chance of receiving effective, tailored therapy, and the situation will only improve as more is learned about the genetic hallmarks of cancer.

"The goal is to understand what the best therapy for every CUP patient is so that we can extend life and improve quality of life," Dr. Raber said. "I think that over the next decade, we will be able to do that. We will be able to much better choose specific therapies for patients based on the profile of their cancer."

Common, yet enigmatic

CUP, largely regarded as a fundamentally unique manifestation of cancer, has long defied the prevailing wisdom of metastasis. Consider the example of a carcinoma found growing in the bone. Carcinomas originate from epithelial cells, so the tumor cannot have originated in the bone—it must be a metastasis that was introduced either through local invasion or via the bloodstream from a distant primary tumor. If no primary carcinoma tumor can be found on physical examination or imaging, the case is considered a CUP.

The exact incidence of CUP in the United States is difficult to determine, though the estimated rate is about 2%–4% of all cancer cases, or several thousand a year, according to the U.S.



CUP can be complex, such as in the case of Betha Cramer. She has a history of endometrial cancer, but her present metastasis does not look like her previous cancer, according to her oncologist, Dr. Raber. On the basis of her cancer profile, Ms. Cramer is about to start treatment with protein-bound paclitaxel (Abraxane), which is indicated for metastatic breast cancer.

“Our goal is not to identify the primary tumor but to choose the best therapy that will extend a patient’s life.”

— Dr. Martin Raber

National Cancer Institute. While most CUP is adenocarcinoma, the cases span the entire spectrum of cancer types.

"CUP is a very heterogeneous group of tumors," said Gauri Varadhachary, M.D., a CUP researcher and associate professor of gastrointestinal medical oncology. "The question we often ask is, what clues can we get from the imaging and laboratory tests to develop a short list of the possible primary cancer profiles, which can then help us treat the disease more specifically? For some cancers, where the treatment is not as

effective, the answer isn't as important. But that is changing because of the emergence of tumor-specific targeted therapies."

Until the past couple of decades, oncologists had few diagnostic tools with the precision, specificity, and sensitivity needed to tackle CUP. Very small primary tumors could escape the view of less sophisticated imaging modalities. Thus, patients were typically treated systemically with a broad spectrum of anti-cancer agents—a scattergun approach that was less than ideal, given the toxicity and variable effectiveness associated with different chemotherapies.

However, as technology caught up, oncologists were able to make more informed treatment decisions. The most valuable advance, according to Dr. Raber, was the development of widely accessible, high-quality imaging modalities, such as the fusion of positron emission and computed tomography known as PET/CT. This technique illuminates active cancer sites in the body at their precise location. Owing to better imaging—and the widespread use of that

imaging—more and more CUP patients are eventually diagnosed with a primary tumor, allowing their therapies to be better customized.

Quality pathologic examination is also an important element in the hunt for a primary tumor, as well— to moderately differentiated cancers can often be identified. Another key has been the refinement of robust immunohistochemical stains, which detect protein markers known to be associated with specific cancer types. Along with imaging and pathology results, immunohistochemical stains have helped physicians learn to effectively divide patients into subsets according to *likely* tissue of origin, and from there choose the best-option therapies.

Oncologists still don't fully understand why some primary tumors are undetectable even as their metastases grow. Many possible explanations for this enduring mystery have been proposed over the years, including:

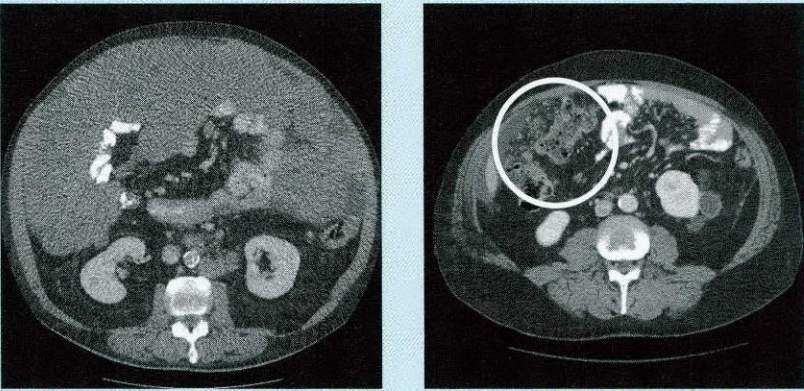
- CUP arises when metastases reach detectable sizes faster than the primary tumor.
- The primary tumor has been reduced or removed by the body's immune mechanism but not before metastatic cells have escaped.
- The primary tumor metastasized while at a detectable size but then regressed through some biologic function before the metastatic sites were discovered.

The truth may lie somewhere in the middle of the various theories. For Dr. Raber, the possible reasons for this disease presentation are interesting but not paramount. "Our goal is not to identify the primary tumor," he said, "but to choose the best therapy that will extend a patient's life."

Following the clues

Given the complexity and heterogeneity of CUP cases, M. D. Anderson relies on a team approach to treating the disease. Cases are typically routed through the Gastrointestinal Center. First, a pathologist studies previous

CUP and Carcinomatosis



Part of the difficulty in treating CUP is the many ways in which the disease can present. For example, these computed tomography images show two very different presentations of peritoneal carcinomatosis (left, cancer [medium gray] fills the entire anterior of the abdomen; right, cancer indicated with the circle). Furthermore, peritoneal carcinomatosis can arise from many primary origins, including primary peritoneal carcinoma and ovarian carcinoma (in women); signet ring cell or non-signet ring cell adenocarcinoma of the stomach, colon, pancreas, or appendix; cholangiocarcinoma; pseudomyxoma peritonei without an obvious primary; and peritoneal mesothelioma (mistaken as carcinoma). Researchers hope to individualize therapy for this entity through development of a robust immunohistochemical and molecular probe platform.

pathology samples to ensure that no indicators of the primary origin have been overlooked. Then, the patient's imaging is reviewed for the same purpose. If the primary origin is still considered unknown, the patient will be seen by one of the institution's CUP specialists. Throughout the treatment process, these lead physicians consult with others whose specialties include diagnostic imaging, pathology, and surgery.

One thing the specialists try to determine early on is whether a case fits any of the unique metastatic patterns that have been documented in CUP. "History has taught us that for 'look-alike' diseases, we can treat them as a known primary," Dr. Raber said. For example, if a woman presents with metastatic adenocarcinoma in the axilla, she is given breast cancer therapy. A man with metastatic squamous cell carcinoma above the supraclavicular region is treated as though he has primary

squamous cell cancer of the head and neck. These patients can be expected to respond as would patients who have metastatic disease of known origin, Dr. Raber said.

Immunohistochemistry

If the clinical presentation doesn't yield any useful clues, the physicians can turn to the increasingly sophisticated array of immunohistochemical stains, which can identify proteins expressed by specific cancer types. "For example, the immunohistochemical marker TTF1 is usually associated with lung cancer, and CUP patients with this marker are treated with a lung cancer regimen," Dr. Varadhachary said. "Patients with cytokeratin 20-positive and cytokeratin 7-negative cancers are treated with an expanded colon cancer regimen."

But immunohistochemical stains have limitations and are not specific, since different types of cancer can

(Continued on page 4)

In Search of the Answer

(Continued from page 3)

express the same proteins. “Currently, for a majority of CUP patients, the stains give us some direction, but they do not give us the answer. Furthermore, there is no direct validation of the test results unless a latent primary tumor appears, a phenomenon that occurs in only 2%–3% of CUP patients,” Dr. Varadhachary said.

One goal for the CUP specialists is to develop a tier system for immunohistochemical stains. With dozens of such tests available, it’s not feasible to perform each one for every case of CUP. However, if the knowledge of common CUP cancers can be translated into immunohistochemical testing guidelines, clinicians could start with the stains most likely to yield useful information, based on the characteristics of a certain case.

Genetic profiling

What’s now shaping up to be a potential breakthrough for CUP treatment is the use of molecular probe

assays to produce a genetic portrait of metastatic tumors. The belief is that genotype analysis will provide a much more specific idea of the originating tissue than immunohistochemistry alone.

M. D. Anderson researchers are now testing molecular probe assays in different cancer types by comparing the assay data to immunohistochemistry data. The goal is to see whether genetic profiling can further refine the subsets established through immunohistochemistry. “We need to demonstrate whether these probes can be used to help us determine the primary, and if we use that molecular determinant to decide which chemotherapy to use, is that helpful?” Dr. Raber said.

Challenges ahead

Despite such promising technology, progress against CUP still faces some of the same basic challenges that it has in the past. There are no large patient associations, as exist for most other

“The question we often ask is, what clues about the disease can help us treat it more specifically?”

– Dr. Gauri Varadhachary

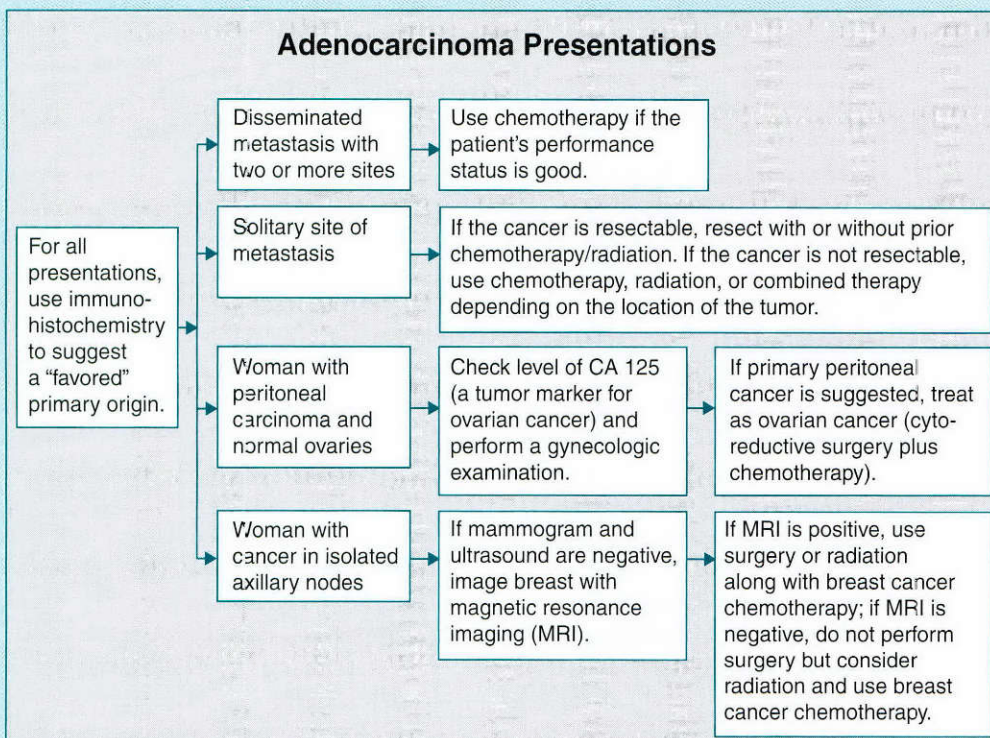
prominent cancer types, to apply pressure for greater funding and research. And, by the nature of CUP, there is no way to prove a certain approach is successful, which further limits opportunities for funding. Anecdotal experience indicates CUP patients are living longer, but no recent studies have evaluated the effects of newer technologies on survival, according to Dr. Raber.

Additionally, relevant information in the literature can be frustratingly sparse.

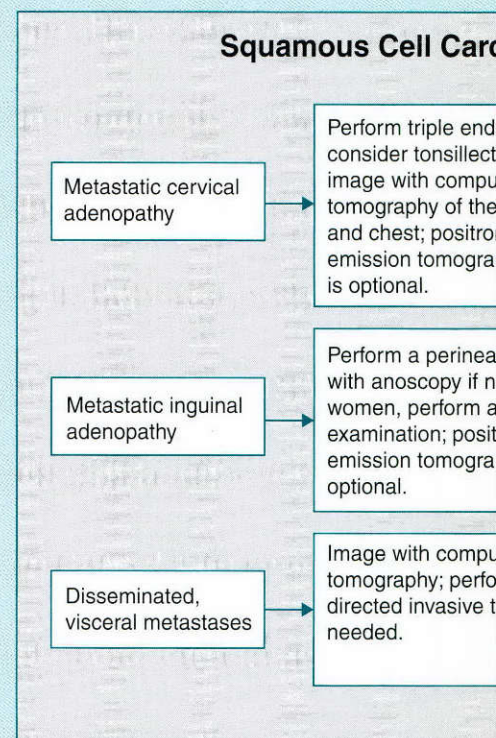
Treatment Algorithms for CUP

Choosing effective treatment for CUP depends on the disease profile, which is determined through clinical evaluation, imaging, biomarkers, and pathologic review. The following are treatment algorithms in place at M. D. Anderson for various presentations.

Adenocarcinoma Presentations



Squamous Cell Carcinoma Presentations



Phase III Trial to Test Drug to Prevent Large B-Cell Lymphoma Recurrence

A clinical trial has opened for an experimental therapy to prevent recurrences in patients with a type of non-Hodgkin's lymphoma. The phase III study of enzastaurin will investigate the drug's ability to prevent relapse and increase overall and disease-free survival in patients with diffuse large B-cell lymphoma. Currently, no treatments are approved to help prevent relapse in such patients.

"Because no drugs exist to prevent relapse in high-risk patients with large B-cell lymphoma, we need to identify an effective maintenance therapy," said Luis Eduardo Fayad, M.D., principal investigator of the trial at M. D. Anderson and an associate professor in the Department of Lymphoma and Myeloma.

The enzastaurin study (called Preventing Relapse in Lymphoma Using Daily Enzastaurin, or PRELUDE) is being conducted at M. D. Anderson and more than 150 other sites. Participants have a 66% chance of receiving daily enzastaurin therapy for up to 3 years and a 33% chance of receiving a placebo.

The standard chemotherapy regimen for large B-cell lymphoma is known as R-CHOP (rituximab, cyclophosphamide, doxorubicin, vincristine, and prednisolone), but about half the patients who achieve remission with this regimen experience disease recurrence within 3 years.

Side effects reported in a phase II study of enzastaurin included fatigue and nausea. No deaths or discontinuation of treatment because of toxicity were reported. Among inclusion criteria for the PRELUDE study are a clinical diagnosis of diffuse large B-cell lymphoma; recent completion of R-CHOP; disease remission; and high risk of disease recurrence as defined by the International Prognostic Index.

For more information, contact Dr. Fayad at lfayad@mdanderson.org

or 713-792-2860, or search for "PRELUDE" at www.clinicaltrials.gov.

Kidney, Liver Cancer Drug May Also Have Anti-leukemia Benefit

Researchers at M. D. Anderson recently discovered that sorafenib, a drug used to treat kidney and liver cancers, also targets a kinase mutation active in about one-third of patients with acute myelogenous leukemia (AML), the most common and lethal form of adult leukemia.

"AML patients with this mutation have a particularly poor prognosis, so this highly targeted drug appears to be a significant step forward in leukemia therapy," said Michael Andreeff, M.D., Ph.D., a professor in M. D. Anderson's departments of Leukemia and Stem Cell Transplantation and Cellular Therapy.

In a phase I clinical trial, sorafenib reduced the median percentage of leukemia cells circulating in the blood from 81% to 7.5% and in the bone marrow from 75.5% to 34% among AML patients with FLT3-ITD, a mutation of the tyrosine kinase FLT3. In two patients, the percentage of circulating leukemia cells dropped to zero.

Patients in the clinical trial have not yet experienced any major side effects, so the maximum tolerated dose has not been reached, Dr. Andreeff said. Sorafenib has little effect on cells in patients with normal FLT3, and the drug does not interfere with normal blood cell formation.

Sorafenib targets tumor cell growth and angiogenesis by targeting two classes of kinases. While the drug's ability to inhibit multiple kinases probably accounts for its anti-leukemia effects, Dr. Andreeff said, the exact molecular mechanisms involved require further study.

"Here we have a great response against an important mutation, but sorafenib alone will not cure patients," Dr. Andreeff said. He and his colleagues plan to examine sorafenib combinations against other diseases

(Continued on page 6)

For example, if a patient presents with a metastatic scalp lesion and no other evidence of disease, it's unlikely that a body of data on the same presentation will be available, Dr. Varadhachary said.

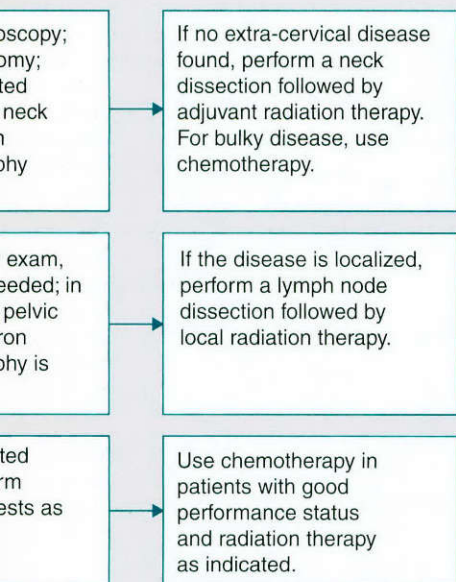
At its core, CUP science remains a process of indirect validation—factoring in all the clues to a cancer's primary origin, deciding on the best course of action, and hoping for a positive response.

"There is still a lot of art in the treatment of unknown primary cases," Dr. Raber said. "When treating a patient, we need to remain humble and realize that we may be on the wrong track and we may need to change focus. After all, it's called unknown primary for a reason." ●

For more information, call Dr. Varadhachary at 713-792-2828, Dr. Raber at 713-563-2192, or the New Patient Referral Office at 1-877-632-6789.

Imaging, testing for serum tumor markers, and other presentations of two CUP types.

Lymphoma Presentations



IN BRIEF

(Continued from page 5)

with the FLT3-ITD mutation.

Currently, a phase I/II clinical trial that combines sorafenib with the standard-of-care chemotherapy combination for AML, idarubicin and cytosine arabinoside, is open at M. D. Anderson. Jorge Cortes, M.D., a professor in M. D. Anderson's Department of Leukemia, said that patients with recurrent AML and those newly diagnosed with the disease are eligible for the study. As safety and dose escalation research progresses, it is hoped that sorafenib will be made available to other patients and assume a role in frontline therapy. ●

PET/CT May Provide Better Detection of Inflammatory Breast Cancer Spread

An imaging technology that can pinpoint active cancer cells in the body is effective at detecting the spread of a rare but very aggressive form of breast cancer, M. D. Anderson researchers reported recently. The technology is PET/CT, a combination of positron emission tomography and computed tomography.

Recent studies showed that PET/CT could identify whether a cancer therapy was working by revealing residual active cancer cells in the body. The researchers decided to test whether such imaging could also spot the spread of inflammatory breast cancer, which represents just 1%–5% of all breast cancers but is more likely than most to be diagnosed after metastasis.

In a study of 41 women with newly diagnosed inflammatory breast cancer, PET/CT correctly identified metastases 95% of the time, as confirmed by biopsy or correlative imaging. The PET/CT scans were 98% accurate in finding spread to local lymph nodes. The method is more accurate—and faster—than traditional modalities for detecting metastasis, which include CT, whole-body bone scan, ultrasonography, and magnetic resonance imaging.

In PET/CT, the patient is first

injected with a radiolabeled glucose substance, which is taken up by metabolically active tumor cells. A PET scanner then detects the radiation emitted from these glucose concentrations, and the resulting image is paired with an anatomically detailed CT scan. In the combination picture, tumors show up as bright spots on what is essentially a crisp, clear x-ray image of the body's structures.

Selin Carkaci, M.D., an assistant professor in diagnostic radiology and presenter of the research, said large-scale trials of PET/CT in inflammatory breast cancer patients may change how the disease is diagnosed and followed. ●

Two Proteins Shown to Destroy Tumor Suppressor Together

Researchers at M. D. Anderson have found that two cancer-promoting proteins work together to negate the protection of a critical tumor suppressor by forcing it from the cell's nucleus and then instructing the body to destroy it.

The findings could lead to new therapeutic targets for cancer focused on FOXO3a, a member of the forkhead family of tumor-suppressing proteins. FOXO3a is inactivated in about 80% of breast tumors, and it's likely to be inactivated in other solid tumors because three major oncogenic pathways separately target it, said Mien-Chie Hung, Ph.D., chair of M. D. Anderson's Department of Molecular and Cellular Oncology and senior author of the research.

FOXO3a and other forkhead proteins have a structure known as the forkhead box that allows them to connect with DNA and in turn activate or repress genes involved in tumor suppression and DNA repair. Dr. Hung and colleagues found ERK, a known oncoprotein, attacks FOXO3a by attaching phosphate groups to it. This phosphorylated FOXO3a is removed from the nucleus and thus can no longer do its job as a tumor-

“ERK alone accounts for 30% of human cancers.

Enhancing FOXO3a could be an effective therapeutic strategy.”

– Dr. Mien-Chie Hung

suppressing protein.

The team's laboratory studies revealed that a second known oncogenic protein, MDM2, completes the attack on FOXO3a by attaching a string of targeting proteins known as ubiquitins to the phosphorylated FOXO3a. This marks it for destruction by the ubiquitin-proteasome degradation pathway.

While both ERK and MDM2 were well known to have cancer-promoting functions, this research shows for the first time that the two work together against tumor suppression, Dr. Hung said.

In a sample of 125 breast cancer tumors, MDM2 expression and low FOXO3a expression were associated with higher-grade tumors. Additional experiments showed that breast cancer cells treated with healthy FOXO3a and injected into mice resulted in barely measurable tumor volumes after 56 days. However, tumors in mice injected with cells that had a disabled version of the tumor suppressor were large.

In addition to ERK, researchers have identified AKT and IKK β as cancer-causing proteins that target FOXO3a through phosphorylation. “At least one of these three pathways is active in about 80% of solid-tumor cancers,” Dr. Hung said. “ERK alone accounts for 30% of human cancers.”

So far, therapeutic agents have targeted the three proteins separately. “But activating these proteins' forkhead target, FOXO3a, would work against all three of them. Enhancing FOXO3a could be an effective therapeutic strategy,” Dr. Hung said.

Results were published in the February 10 issue of *Nature Cell Biology*. ●



The Basics of Biopsies

If your doctor thinks you might have cancer, you will probably undergo a procedure known as a biopsy. There are many types of biopsies, but in all types, a doctor will remove a sample of tissue from your body. The tissue sample will then be examined for evidence of cancer.


The idea of a biopsy—let alone cancer—can be frightening. But it may ease your worries to know more about the different types of biopsies and what happens after the procedure.

Before the biopsy

A biopsy is done at a spot where tissue appears to be growing abnormally. Before the biopsy, your doctor will usually perform other tests (such as scans or blood tests) to see if cancer can be ruled out. If cancer can't be ruled out, a biopsy can determine whether the growth is malignant (cancerous) or benign (non-cancerous).

Types of biopsies

- **Fine needle aspiration** (also called FNA) is a common type of biopsy that uses a thin needle about the size of an injection needle. The doctor inserts the needle through the skin and into the growth to collect cells for testing. You usually won't need any anesthesia, and results are usually available within hours.
- **Core needle biopsy** uses a larger needle to withdraw a small core of tissue from the growth. The needle is inserted through a small cut made in the skin. A local anesthetic is usually given at the insertion site. Afterward, you may have bruising at and around the site. If the growth is difficult to feel through the skin, the doctor may use ultrasound or another type of imaging to help guide the needle.



**A biopsy
can determine
whether a growth
is cancerous.**

- **Endoscopic biopsy** is done with a thin, flexible tube that has a light or camera on one end. The tube is inserted through a cut in the skin or a natural opening, such as your mouth, and guided to the growth. There, the doctor can collect a cell sample using small scissors, a brush, or a needle attached to the end of the tube. Sometimes a sedative or local anesthetic is used with endoscopic biopsy.
- **Incisional biopsy** is done by making a surgical incision and removing a portion of a growth for testing. This is most commonly done for extremely large masses in soft tissue (such as muscle, fat, and connective tissue). Incisional biopsy usually requires a local or general anesthetic

and should be performed by an experienced surgeon.

- **Excisional biopsy** involves complete removal of a tumor. Excisional biopsies are usually performed for small growths, such as those on the skin. Like incisional biopsy, excisional biopsy usually requires a local or general anesthetic and should be performed by an experienced surgeon.

Your doctor can explain which procedure is best for you and why.

After the procedure

Tissue collection is just the first part of a biopsy. The second part is done in a laboratory by a pathologist, a doctor who is trained to examine the tissue for any evidence of cancer. The pathologist will place small amounts of your tissue on glass slides, stain them with chemicals, and look at them under a microscope. To a pathologist, cancer cells usually look very different from normal cells.

The pathologist will write a report on the biopsy findings and give it to your doctor. If the growth is cancer, your doctor will discuss treatment options with you.

Will a biopsy cause cancer to spread?

A biopsy will almost never cause cancer to spread. If you are worried about this possibility, ask your doctor to explain the steps that will be taken to make sure the biopsy is done safely. ●

For more information, talk to your physician, or:

- call askMDAnderson at 1-877-632-6789
- visit www.mdanderson.org

OncoLog, March 2008

©2008 The University of Texas
M. D. Anderson Cancer Center

Address Service Requested

DiaLog Mapping the Cancer Genome

By Gordon Mills, M.D., Ph.D.

With the completion of the Human Genome Project, biomedical research is poised to make significant strides in the individualized treatment of disease. Many feel that this will bring more precision—and greater success—to medical diagnosis and care. For cancer, we can finally develop a systematic understanding of the processes that drive the development and progression of the disease.

An exciting new pilot project, the Cancer Genome Atlas, will provide a first step in that direction through large-scale genetic analysis of certain cancer types. M. D. Anderson and other leading U.S. cancer centers play significant roles in this 3-year, \$100 million, nationwide collaboration headed by the U.S. National Cancer Institute and the National Human Genome Research Institute.

The pilot project focuses specifically on glioblastoma multiforme, squamous cell carcinoma of the lung, and serous cystadenocarcinoma of the ovary. The goal is to characterize the genomic and transcriptional aberrations in 500 variations of these cancers, creating a genetic “fingerprint” of each. Data from the project will be stored in free public databases for use by the cancer research community. This genomic atlas will expand our knowledge of molecular targets in these diseases and help us define new ways to classify tumors so that treatments can be more specifically

matched with the patients most likely to benefit. If successful, the pilot project will lead to a full-scale project to map the molecular changes that take place across all human cancer types.

M. D. Anderson has been involved in many facets of the Cancer Genome Atlas, beginning with representation on the steering committee. For the pilot project, we are providing the majority of the tissue samples for the three tumor types under study. We are the only institution providing analysis of DNA copy numbers and allelotypes for the project, using a new genomic technology called the molecular inversion probe assay. M. D. Anderson has extensive technical expertise in using this technology, which is superior to current high-throughput analysis in its specificity and its ability to analyze large numbers of gene sequences at one time. We are also developing a user-friendly interface for the data so that researchers can easily access it as it becomes available.

The Cancer Genome Atlas has enormous potential to deepen our understanding of cancer biology and to pave the way for more effective treatments. At M. D. Anderson, we are excited and optimistic about the possibilities. ●



Dr. Mills is director of the Kleberg Center for Molecular Markers and chairman of the Department of Systems Biology at M. D. Anderson.

OncoLog

The University of Texas
M. D. Anderson Cancer Center

President

John Mendelsohn, M.D.

Provost and Executive Vice President

Raymond DuBois, M.D., Ph.D.

Senior Vice President for Academic Affairs

Stephen P. Tomasovic, Ph.D.

Director, Department of Scientific Publications

Walter J. Pagel

Managing Editor

John LeBas

Contributing Editors

Melissa G. Burkett

Virginia Mohlere

Joe Munch

Lionel Santibañez

Ann M. Sutton

Design

The Very Idea®

Photography

Jim Lemoine

Editorial Board

Michael Fisch, M.D., Chair

Lyle Green, Vice Chair

Therese Bevers, M.D.

Robert Gagel, M.D.

Beverly Handy, M.D.

Patrick Hwu, M.D.

Charles Koller, M.D.

Maurie Markman, M.D.

Shreyaskumar Patel, M.D.

David Schwartz, M.D.

Rena Sellin, M.D.

Randal Weber, M.D.

Christopher Wood, M.D.

Physicians: To refer a patient or learn more about M. D. Anderson, please contact the Office of Physician Relations at 713-792-2202, 1-800-252-0502, or www.mdanderson.org/departments/physrelations.

Patients: To refer yourself to M. D. Anderson or learn more about our services, please call 1-877-632-6789 or visit www.mdanderson.org.

For questions or comments about *OncoLog*, please e-mail scientificpublications@mdanderson.org or call 713-792-3305. Current and previous issues are available online in English and Spanish at www.mdanderson.org/oncolog.

Made possible in part by a gift from the late Mrs. Harry C. Wiess.