

A Publication of
**M. D. Anderson
Cancer Center**
Making Cancer History™

4

Beyond the Brain
Researchers are treating
spinal tumors with
stereotactic radiotherapy.

7

House Call
For women who
smoke, sobering statistics
but also hope.



8

DiaLog
Engineered tissue has poten-
tial applications in both the
clinic and the laboratory.

03-452
RECD SEP 12 2003

**NON-CIRCULATING
U of NT
REPORT TO PHYSICIANS**

FEBRUARY 2003 Vol. 48, No. 2


Oncolog

Tissue Engineering: Several Avenues of Research Lead Toward a Single Goal

by Sunni Hosemann

Advances in autologous tissue transplantation have greatly improved the repair of defects left by cancer and cancer treatments. Nevertheless, many plastic surgeons believe they can do better. Flap and graft transplantations require at least one additional operative site, with consequent additional recovery time and the potential for morbidity. In addition, the amount of tissue that can be taken from a donor site is limited, and finding enough tissue to replace large defects is difficult.

To address these shortcomings, researchers are attempting to engineer tissue that can be used to repair and restore defects. For oncologic reconstruction, "The ultimate goal is to be able to make three-dimensional constructs shaped to the exact size of the tissue defect to be repaired—a living replica of the tissue that was removed," said reconstructive surgeon Elisabeth



Several researchers in the Department of Plastic Surgery at M. D. Anderson Cancer Center are working on various aspects of engineered tissue development. Examining a section of artificial skin in the laboratory are **Dr. Charles Patrick, Jr.**, (left), an associate professor and director of research in the department, and **Dr. Charles Butler**, an associate professor in the department and director of the Plastic Surgery Clinic.

Beahm, M.D., an associate professor in the Department of Plastic Surgery at The University of Texas M. D. Anderson Cancer Center.

Materials used to make these tissue constructs, or engineered tissue substitutes, must have certain physiochemical properties to be biologically active and allow cellular infiltration, vascu-

larization, degradation, and replacement with host tissue to occur over time.

The ideal replacement tissue contains

(Continued on next page)

THE UNIVERSITY OF TEXAS
MD ANDERSON
CANCER CENTER

Tissue Engineering Research Involves Several Avenues of Study

(Continued from page 1)

organ-specific or site-specific cells from the patient. Theoretically, cells from a small tissue biopsy, expanded in cell culture, can be combined with biodegradable scaffolds and other factors to yield a nearly unlimited amount of certain tissues. Charles Butler, M.D., an associate professor in the Department of Plastic Surgery and director of M. D. Anderson's Plastic Surgery Clinic, envisions profound potential for tissue engineering: new skin, bone, fat, and cartilage, even new organs to replace diseased ones. "Consider a firefighter who sustains deep burns over large areas of his body. The physicians treating him could rapidly generate new skin for any part of his body, derived from his own donated cells. His skin cells could have been collected from a small biopsy when he signed on his job and banked for this purpose," said Dr. Butler, whose research interest focuses largely on engineering skin and other epithelial tissues.

In fact, it is nearly impossible to exaggerate the potential of tissue engineering technology. Likewise, it is difficult to overstate the complexity of producing clinically viable engineered tissue. To manipulate cells to grow, develop in specialized ways, and sustain their life without becoming abnormal, tissue engineers must come to understand things about cells that are not now known. This will not be the work of one scientist, nor the work of one branch of science, but the collaboration of many—life scientists, bioengineers, and clinicians.

Many and varied research questions must therefore be addressed, one of the most important and fundamental being how to establish a blood supply. The complexity of this task depends on the tissue to be manufactured. "Cartilage, for example, is relatively avascular and has very low metabolic requirements. Epidermis can survive by nutrient diffusion. But all other tissues require a patent microvascular system, so the study of angiogenesis on a cellular and molecular level is one of the crucial aspects of this research," said Charles Patrick, Jr., Ph.D., an associate professor and director of research in the Department of Plastic Surgery. Dr. Patrick,

Tissue Engineering: How It's Done

The basic strategy for developing engineered tissues is to create a structure and an environment where cells—ideally autologous cells harvested from a small biopsy—can grow and differentiate to become the needed tissue. The main components of such a system are the cells themselves (inside a specially designed microenvironment), a scaffold, and an incubation environment, or bioreactor.

The microenvironment includes the tissue cells and other ingredients such as support cells, growth factors, genetic factors, and other components that will help regulate and control cell growth. It also may contain drugs such as antibiotics, as well as other chemical agents that can influence such cell behaviors as proliferation, differentiation, and migration. Synthetic systems that can control the release and delivery of drugs and other chemical factors may also be part of the design.

The scaffold may be made of natural, synthetic, or hybrid material. Synthetic polymers are often used since they can be chemically manipu-

lated to achieve the optimum shape, configuration, porosity, biomechanics, and surface design. Some scaffolds are woven or nonwoven meshes, some resemble sponges or foams, and others are hydrogels that can be injected to repair internal defects. In some cases, the scaffold is a permanent part of the tissue construct, but scaffolds can be chemically programmed to biodegrade and disappear as the tissue grows.

The bioreactor is the environment used to incubate the growing tissue. Small volumes of simple tissues can be grown for short periods of time in fairly conventional laboratory apparatuses: a petri dish and incubator, for example. But more sophisticated environments will be necessary for real clinical applications of this technology, as the interactions among the scaffold, its seeded material, and the bioreactor can be manipulated to maximize cell viability and stability. Mechanically active, rotating bioreactors are one possible model; in another, the scaffold and microenvironment are implanted, and the patient becomes the bioreactor. ●

whose research focuses on the synthesis and composition of biomaterials needed for the scaffold and the microenvironment of engineered tissue, coupled with cell biology and clinical science, collaborates extensively with chemical engineering colleagues at Rice University and The University of Texas, as well as with his Plastic Surgery colleagues.

While scientists are learning a great deal about angiogenesis in tumors, little is known about neovascularization—the formation of capillary networks—in engineered tissue. One of the challenges is that vessels at the capillary level are so small that they are difficult to see, even with sophisticated imaging modalities. This is one area of interest for Greg Reece, M.D., a professor in the Department of Plastic Surgery whose specialty in microvascular surgery has

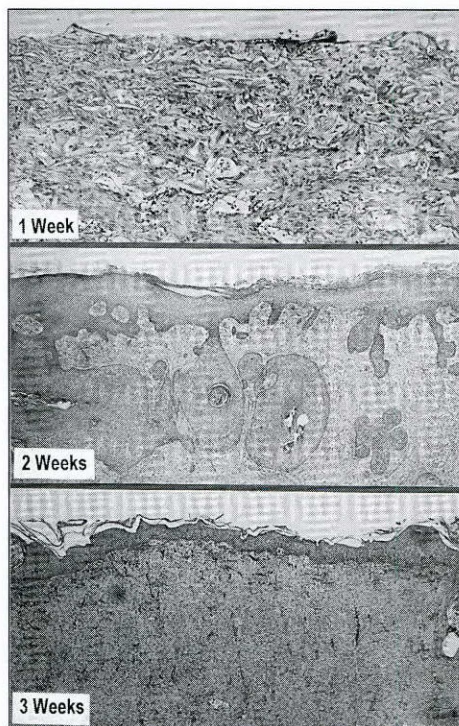
led him to try to measure the number and morphology of these tiny vessels.

Dr. Reece and his colleagues in the Department of Plastic Surgery have produced what may be the first three-dimensional images of capillaries growing across the interface between a skin graft and the wound bed of the recipient site. Dr. Reece acquires the skin grafts from a small animal model, and histotechnologist Carol Johnston serially sections each specimen (the graft and underlying wound bed) on a cryostat. Xuemei Wu, M.D., a senior research assistant, then stains the sections with an antibody against the lining of the blood vessels. A computer-operated microscope produces serial images of each histologic section, which are then tiled together to make a single, digitized mosaic image, similar to a

satellite photograph. Each tiled image is then assigned two colors: red for blood vessels and black for everything else. Using a computer program designed by Dr. Patrick and Eric Brey, a Rice University graduate student, the tiled images are realigned into a single three-dimensional image that allows the researchers to quantify the blood vessels and determine their histomorphology.

"This is very difficult to do, however, because it relies on the expertise of the histotechnologist in serial sectioning and requires the computer to align the serial tiled images with an accuracy of a quarter of a micron," said Dr. Reece. In addition, he said, the technique is a one-time view of blood vessel growth in the tissue sample, not a way to observe what is happening over time within the tissue. But it is an important first step, offering visual evidence of blood vessel growth into the natural fibrin gel that bridges the interface between the graft and the wound. But, said Dr. Reece, "There is much to be discovered before we are able to learn how to distribute a new microvasculature over a large tissue construct in the same way Mother Nature does in a conventional tissue graft."

In addition to providing adequate vascularization for engineered tissue, researchers must overcome the challenge of creating and maintaining a three-dimensional tissue construct that is large enough to be clinically relevant. "We must also ensure that the induced tissue reaches equilibrium and does not become malignant tissue—as growth factors and other factors involved in angiogenesis and adipogenesis are also intimately involved in tumor formation," said Dr. Beahm, whose research focuses on engineering adipose tissue for soft tissue repairs. Furthermore, growth factors used for tissue induction are species specific, so the path from small to large animal models is not direct, and there is much to be learned. "Translational research and long-term studies in large animals are critical," Dr. Beahm said. "This is a series of small projects, but it will be extraordinary indeed when we are able to create three-dimensional, vascularized fat constructs."



Histologic cross sections of keratinocyte-seeded collagen-glycosaminoglycan (CG) matrices show the simultaneous formation of dermal and epidermal tissue. At one week, most of the CG matrix remains undegraded, and cellular infiltration and neovascularization are located mostly in the lower half of the graft. At two weeks, however, the epidermis and neodermis have changed dramatically. The CG matrix is now completely infiltrated with cells and blood vessels, and a confluent, multilayered, stratified epidermis is seen. In the neodermis, keratinocyte cysts have formed from the proliferation of keratinocytes that were unable to completely traverse the matrix to the silicone-matrix junction during centrifugation. At three weeks, the CG matrix has been completely replaced with vascularized neodermis, and the keratinocyte cysts are completely absent, having unidirectionally migrated through the developing neodermis to fuse with the epidermis and help form it.

Skin is critical for oncologic reconstruction because cancer treatment frequently requires the resection of skin and subcutaneous tissue, which are usually replaced with skin grafts or tissue flaps. With his colleagues at Harvard University and Massachusetts Institute of Technology, Dr. Butler has developed a tissue-engineered skin substitute that simultaneously regenerates both dermis and epidermis and can be grafted during a single procedure. Production of this skin substitute involves impregnating a specialized, biodegradable synthetic construct with host skin cells derived from a small skin sample. Because tissue properties such as thickness, color, elasticity, and the presence of hair follicles and glands vary depending on where the tissue is located, the goal is to regenerate tissues that closely match the recipient site. Dr. Butler and his colleagues are studying the skin substitute in animal models and hope to begin clinical trials in patients soon.

Protocols are also under way to study the prefabrication and prelamination of specialized tissues such as those that make up the nipple and areola of the breast, oral mucosa, lips, and vaginal mucosa. Dr. Butler and his colleagues have been able to regenerate oral


mucosa with a technique using cells from the oral cavity. He is also working to develop more sophisticated tissue flaps that contain more than one type of site-specific tissue. These "custom" tissue flaps will be used to repair complex composite defects that involve several types of tissue.

Repairing defects in bone involves challenges similar to those encountered in soft tissue repair: the shortage of harvest sites, the need for a blood supply, and the difficulty of re-creating special functions. In addition, bone has greater structural duties and must be prefabricated in an exact shape and size. "My research in this area focuses on creating a large animal model to use as a platform to understand and assess the effectiveness of different tissue engineering methods," said Michael J. Miller, M.D., a professor in the Department of Plastic Surgery. "We need to work with bones that are large enough to require a blood supply similar to that of a human femur." In a recent protocol using tissue engineering principles in large animal models, Dr. Miller and his colleagues created a mandible that was engineered in synthetic scaffolds using osteogenic cell populations and bone induction factors and attached it to the blood

(Continued on page 4)

Tissue Engineering

(Continued from page 3)



Dr. Michael J. Miller, a professor in the Department of Plastic Surgery, is developing engineered bone to replace skeletal defects.

supply of the periosteum. This technique may soon be used for the first time in a human—a young patient who lost all of the bones of her nose, palate, and the base of her skull to chondrosarcoma.

In yet another avenue of tissue engineering research, Dr. Miller, in collaboration with Dr. Patrick and other colleagues at the University of Houston and The University of Texas, is working with computer simulation models. In a current protocol, the researchers are creating computer simulations of the breast that will characterize the defect to be repaired using sophisticated measurements and modeling of the size and proportion of the tissue and its biomechanical properties. The simulations will also take into account density and elasticity, which govern how the tissue moves and how it is affected by gravity. Eventually, such a simulation will characterize the three-dimensional aspects of a defect and generate a blueprint for building the scaffold, as well as a recipe for the tissue micro-environment. ●

FOR MORE INFORMATION, contact the Department of Plastic Surgery at (713) 794-1247.

Researchers Design a Unique Stereotactic Radiosurgery System to Treat Paraspinal Tumors

by Dawn Chalaire

With the development of a unique stereotactic radiotherapy and radiosurgery (SRT/SRS) system that precisely delivers high doses of radiation to paraspinal tumors, researchers at The University of Texas M. D. Anderson Cancer Center are taking the first steps toward expanding the use of stereotactic radiation delivery beyond the treatment of tumors in the brain.

“It’s very challenging to do stereotactic treatment outside of the brain,” said Eric L. Chang, M.D., an assistant professor in the Department of Radiation Oncology and radiation oncologist in charge of the new stereotactic spine radiotherapy program at M. D. Anderson, a collaborative effort between the Division of Radiation Oncology and the Department of Neurosurgery. “For intracranial radiosurgery, the skull can be fixated in space with neurosurgical screws. Immobilization, which is crucial for any stereotactic treatment, is a tour de force for lesions outside the brain because the body is made up of soft tissues that are difficult to immobilize and can move in relation to one another.”

Dr. Chang is the principal investigator leading a phase I/II clinical trial to evaluate the safety and feasibility of a painless, noninvasive spinal SRT/SRS system in patients with one or two paraspinal metastases. He and co-investigators Almon Shiu, Ph.D., an associate professor in the Department of Radiation Physics, and Laurence Rhines, M.D., an assistant professor in the Department of Neurosurgery, also are gathering evidence to determine whether the treatment relieves or prevents pain and other symptoms associated with spinal tumors, including neurologic dysfunction, pathologic fractures, and spinal instability.

“Unfortunately, it’s a common situation in many cancers, especially breast, lung, and prostate cancers, that metastatic tumors affect the vertebrae. When the tumors progress, they invade the spinal cord and cause paraplegia, a

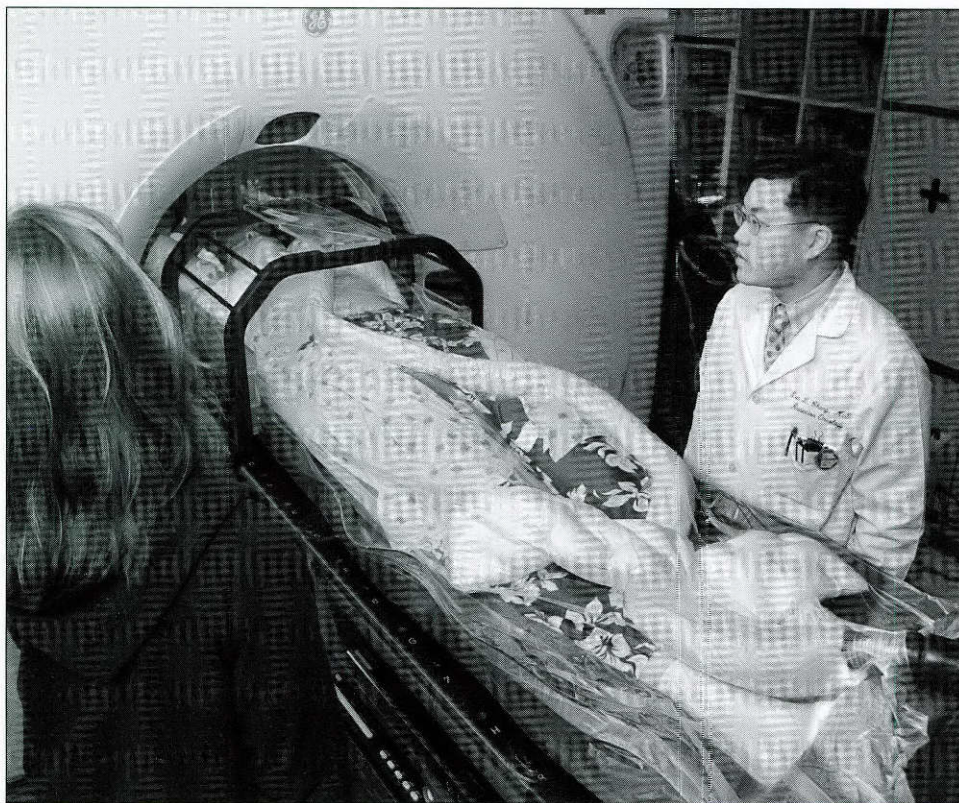devastating neurological condition. We would like to treat the spine but without the side effects, without giving a significant dose [of radiation] to the spinal cord. So precision is very important in the treatment of these patients,” said Moshe Maor, M.D., a professor in the Department of Radiation Oncology.

Dr. Maor knows a great deal about the precise delivery of radiation. A decade ago, he and Dr. Shiu began using stereotactic radiosurgery (SRS) to treat patients with brain tumors. SRS overcomes the radioresistance of many metastatic brain tumors by delivering a high dose of radiation in a single fraction.

Several hundred patients have undergone SRS treatment for brain tumors, and the results are excellent. The control rate in all brain metastases is at least twice that of conventional radiation therapy, and in radioresistant metastases, such as those from renal cell carcinoma, sarcoma, and melanoma, the control rate is 65% to 80% higher than with conventional radiation therapy. This success has led researchers at M. D. Anderson and elsewhere to attempt to expand the applications of SRT/SRS to critical areas outside the brain.

The spine, with its propensity for developing metastatic disease and its proximity to the spinal cord, was a logical choice for an initial attempt at extracranial SRT/SRS. But investigators first had to overcome the problem of movement. In SRS to the brain, the stereotactic coordinates of the treatment isocenter can be transferred with confidence to a metal head frame that will not allow the patient to move, but

Stereotactic Radiotherapy and Patients with Paraspinal Metastases



Dr. Eric L. Chang, an assistant professor in the Department of Radiation Oncology, stands by as **Lisa Ciuray**, a radiation therapist, moves **Pam Melser** into position for computed tomographic imaging during a “dry run” to test the newly developed stereotactic radiotherapy and radiosurgery (SRT/SRS) system to treat paraspinal metastases. Melser is encased in plastic sheeting to immobilize her during the procedure.

the treatment target in spinal tumors must be transferred in a different way and then verified before treatment.

This verification is made possible by a unique combination of immobilization techniques and the use of a recently installed combined computed tomography (CT)-linear accelerator unit, the acquisition of which was spearheaded by James D. Cox, M.D., professor and head of the Division of Radiation Oncology (please see related article in the December 2002 issue of *OncoLog*). With the combined CT-linear accelerator, a single treatment table rotates 180 degrees and a CT scanner moves on rails, making it possible to take CT images and deliver radiation therapy while the patient remains in the same treatment position.

Dr. Shiu, who has overseen the development of SRT/SRS at M. D. Anderson from the very beginning, modified a commercial body immobilization system to the new spinal SRT/

SRS technique. While patients lie supine on a Styrofoam cushion, air is extracted from the cushion to mold it to the underside of the body. (The cushion retains the patient's impression so that the position can be duplicated throughout subsequent imaging and treatment.) A plastic sheet is placed over the patient and carefully adhered to the sides of the cushion until it is airtight. Then a vacuum hose attached to the sheet removes all of the air inside until the plastic clings tightly to the patient's body, minimizing vertebral body motion associated with breathing during CT imaging and treatment delivery. A three-sided localization frame attaches to the treatment table, over the target area, and rods on the edges of each of the frame's three panels serve as reference points in the stereotactic coordinate system.

“But we are still missing the rigid link between the patient's anatomy and the

stereotactic coordinate system,” said Dr. Shiu. “By fusing the daily pretreatment CT images with the planning CT images, we can determine how the patient, especially the vertebral body target, has been shifted, rotated, or both with respect to the setup position of simulation.”

After dosimetry calculations are completed, planning CT scans of the treatment area are taken and used to generate a pair of digital reconstructive radiographs (DRRs) showing the treatment isocenter and surrounding patient anatomy. Later, on the treatment day, CT images of the patient are taken prior to treatment. These daily CT images are fused with the planning CT images to see if the patient has shifted or rotated. Based on this information, a pair of daily DRRs with the updated isocenter are generated. These daily DRRs are compared with the planning DRRs and, if necessary, fine adjustments are made. Then, the corrected isocenter is marked on the positioning frame to align the target isocenter with the linear accelerator's radiation isocenter using lasers. Prior to the delivery of radiation, orthogonal portal images are acquired and compared with the planning DRRs for a final verification. Immediately after treatment, another CT is taken and compared with the daily CT to see if any movement occurred during treatment.

“The radiation treatment plan is developed from a planning CT image taken on the simulation day. On the day of treatment, the patient's body could have moved from the simulated treatment position. A near-real-time CT image taken right before treatment is used for comparison with the planning CT so that any discrepancy in patient positioning can be corrected immediately,” said Dr. Chang.

The precise delivery of SRT/SRS makes it possible to treat tumors with higher doses of radiation without damaging adjacent tissues. The current study calls for five fractions, each

(Continued on **page 6**)

Researchers Design Unique Stereotactic System

(Continued from page 5)

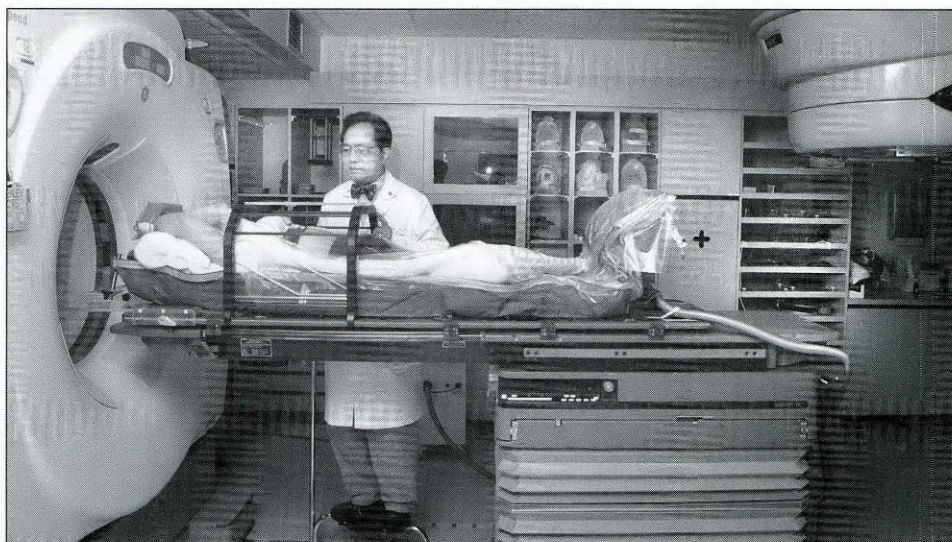consisting of a 6-Gy dose. Giving higher doses of radiation per fraction serves two purposes: it allows for fewer fractions to achieve the total dose, thus limiting the number of times the complicated SRT/SRS procedure has to be performed, and it may overcome radioresistance in some spinal tumors.

“Radiation therapy doses that we’ve been able to use with conventional radiation therapy have been limited by what the spinal cord can tolerate,” said Dr. Rhines. “As you can imagine, there are certain types of tumors whose lethal dose is less than what the spinal cord can tolerate. And so if you give up to the tolerated dose, those tumors are treated effectively. But there are a whole host of other tumors—renal cell carcinoma, sarcomas, etc.—that if you don’t give anything more than what the spinal cord can tolerate, the tumors are not effectively treated. So what stereotactic radiosurgery allows us to do is plan a radiation treatment that delivers much more radiation to the tumor and spares the spinal cord.”

Typically, Dr. Chang said, the risk of paralysis precludes a second course of conventional radiation therapy to the spine. Because SRT/SRS can spare the spinal cord from a clinically significant dose of radiation, however, the current study is open to patients who have previously had radiation therapy to the spine.

“Many patients who have been previously irradiated develop recurrent disease and at that point, their only option is a major surgery that involves surgical risks, recovery time, and rehabilitation,” said Dr. Chang. “Of course, there are situations when surgery is the best and only option, but there are also other cases where the surgeons prefer not to operate and wish they had a noninvasive alternative. The new stereotactic spine radiotherapy program is being developed to help meet that need.”

Historically, Dr. Rhines said, surgeons at M. D. Anderson have treated spinal metastases very aggressively and have had good success with surgical techniques to restore function and reduce pain. “But it’s still a lot for the patients to go through,” he said. “If the



Dr. Almon Shiu, an associate professor in the Department of Radiation Physics, prepares a patient for spinal stereotactic radiotherapy and radiosurgery (SRT/SRS) in the combined computed tomography-linear accelerator treatment room (top photo).



At right, **Dr. Laurence Rhines**, an assistant professor in the Department of Neurosurgery, discusses radiographic images with patient **Katherine Nichols**.

same thing could be done with a noninvasive treatment that I can do with a scalpel, I think that’s a tremendous advantage for the patient.”

In addition, many patients with spinal metastases are not eligible for surgery because they are too sick to undergo anesthesia, their overall disease is too advanced, or the tumor is located in an area that makes its removal unfeasible. Chemotherapy is sometimes used to treat spinal metastases, but it is not always effective, and systemic therapy is often avoided in patients with limited disease.

Dr. Rhines, who also directs the Spine Program in the Department of Neurosurgery, uses his experience to help select patients for the spinal SRT/SRS protocol. “Because of the volume of patients we see, we’re able to make some predic-

tions about how a patient’s spine tumor might behave, and this helps guide our treatment. Patients with spinal fractures, cord compression, or evidence of instability may be better treated with surgery. Stereotactic radiotherapy can then be used postoperatively or at the time of recurrence,” he said.

The investigators hope to accrue 90 patients into the ongoing clinical trial. If the SRT/SRS system is shown to be safe and effective, the next step will be to investigate even shorter courses of SRT/SRS to the spine involving three and, ultimately, a single fraction of radiation. ●

To obtain an informational videotape or to refer patients for the CT-guided stereotactic spine radiotherapy protocol, contact Leni Mathews, R.N., at (713) 792-3332.



Women and Lung Cancer: News You Can Use

Teenage girls do it to look sophisticated. Harried women do it to relieve stress or to keep their weight down. Women start smoking for many different reasons, but the consequences of cigarette use are devastatingly similar—what the Office of the U.S. Surgeon General calls a “full-blown epidemic” of smoking-related diseases among women.

Since 1950, the number of women who die of lung cancer each year has increased 600%, according to a 2001 Surgeon General’s report on “Women and Smoking.” More than 22 million women and 1.5 million adolescent girls in the United States smoke cigarettes, and the number of smokers is increasing the fastest among girls in middle school and high school.

More women die of lung cancer than of any other type of cancer, including breast cancer. Every year, about 68,000 women die of the disease, and smoking, according to the American Cancer Society (ACS), is to blame for about 80% of these lung cancer deaths. The ACS estimates that 80,100 new cases of lung cancer will be diagnosed in women during 2003.

A woman doesn’t have to smoke to be harmed by tobacco. A nonsmoker who breathes in other people’s smoke also has an increased risk of lung cancer. A nonsmoker who is married to someone who smokes, for instance, has a 30% greater risk of lung cancer than the spouse of a nonsmoker.

The good news is that stopping smoking can significantly reduce a woman’s chance of getting lung cancer. In a report published in the *British Medical Journal* in 2000, a group of British epidemiologists found that the risk of lung cancer was lowered by one third in smokers who had quit smoking less than ten years earlier. For those who quit smoking more than 30 years ago, the risk of getting lung cancer was only 10% what it would have been had they continued to smoke.

THE BAD NEWS:

More women die of lung cancer than of any other type of cancer, including breast cancer.



THE GOOD NEWS:

Stopping smoking can significantly reduce a woman’s chance of getting lung cancer.

What Women Can Do to Protect Themselves from Lung Cancer

- **Stop smoking.** Many health agencies offer smoking cessation programs. Nicotine replacement products, which provide small, steady doses of nicotine to relieve withdrawal symptoms, have helped some smokers to quit. These products come in the form of patches, gum, nasal spray, and inhalers. (Combining the nicotine patch with the gum or nasal spray has been shown to increase long-term success rates over using only one nicotine replacement method.) Also, your doctor may be able to prescribe a medication that will help curb your urge to smoke.
- **Try again to stop.** Many smokers have a hard time quitting. Studies have shown that it may take two or three attempts before they can stop for good. The repeat effort is worth it. People who stop smoking for three months often remain cigarette-free for the rest of their lives, according to the National Cancer Institute.
- **Avoid breathing other people’s smoke.**
- **Get more information.** The Cancer Information Service (1-800-4-CANCER) can provide you with free literature about lung cancer or stopping smoking. ●

For more information, contact your physician or contact the M. D. Anderson Information Line:

- ☎ (800) 392-1611 within the United States, or
- ☎ (713) 792-6161 in Houston and outside the United States.

February 2003


©2003 The University of Texas
M. D. Anderson Cancer Center

DiaLog

Applying Tissue Engineering Techniques in the Clinic and the Laboratory

Michael J. Miller, M.D., F.A.C.S.
Professor, Department of
Plastic Surgery

All cancer therapies can lead to the loss of normal tissue function. Surgery can cause deformities and disabilities due to the loss of normal anatomy. Radiotherapy can cause local tissue damage that can lead to pain, chronic wounds, and functional impairment. Even chemotherapy can cause physical deformities when normal tissues are exposed to high doses or when immunosuppression results in destructive opportunistic infections



Tissue engineering—a new field that applies the principles of engineering and life sciences to the development of biological substitutes that restore, maintain, or improve tissue function—has two potential applications in oncology: clinical tissue replacement and the creation of research “tissues” as an alternative to using laboratory animals.

Current methods of oncologic reconstructive surgery rely on harvesting mature tissues from an uninjured site on the patient and then transferring and manually altering the donor tissue to simulate the missing tissue elements. Despite enormous advances in recent years, however, these procedures continue to be time-consuming and technically challenging. They also create donor site deformities and yield tissue that is not

“In the long term, tissue engineering offers the promise of revolutionizing health care, prolonging and improving the quality of life for millions of people around the world, and greatly reducing the cost of treating debilitating diseases.”

— **Elbert Marsh, Deputy Assistant Director for Engineering, National Science Foundation**

a precise replacement. Tissue engineering may overcome these limitations by providing tissues that can be modified at the cellular and molecular levels to precisely replace missing parts without creating donor site problems.

The other application for tissue engineering in oncology is basic research. Research using laboratory animals can be expensive and controversial, and it sometimes yields misleading results. Tissue engineering might lead to the fabrication of living tissues for laboratory study. Experimental human tissues could then be used to study tumor biology, leading to a better understanding of cancer and allowing researchers to evaluate the response of a patient to various treatment modalities without risking toxic effects or complications.

Researchers in the Laboratory of Reparative Biology and Bioengineering here in the Department of Plastic Surgery are investigating bone, fat, and skin tissue engineering and using advanced computing to develop digital tissue simulations needed for custom tissue design. In this emerging field of tissue engineering, as in all areas of oncology, we are committed to remaining at the forefront of research and treatment.

OncoLog

The University of Texas
M. D. Anderson Cancer Center

President
John Mendelsohn, M.D.

**Executive Vice President
and Chief Academic Officer**
Margaret L. Kripke, Ph.D.

Vice President for Educational Programs
Stephen P. Tomasovic, Ph.D.

**Director, Department of
Scientific Publications**
Walter J. Page

Managing Editor
Dawn Chalaire

Contributing Editors
David Galloway
Sunni Hosemann
Katie Matias
Karen Stuyck

Design
The Very Idea®

Photography
Jim Lemoine

Editorial Board
Rena Sellin, M.D., Chair
Therese Bevers, M.D.
Thomas Burke, M.D.
David Callender, M.D.
Ka Wah Chan, M.D.
Steven Curley, M.D.
Eduardo Diaz, Jr., M.D.
Larry Driver, M.D.
Frank Fossella, M.D.
Lewis Foxhall, M.D.
Robert Gagel, M.D.
Sergio Giralt, M.D.
Martyn Howgill
Jeffrey Lee, M.D.
Charles Levenback, M.D.
Moshe Maor, M.D.
Shreyaskumar Patel, M.D.
Geoffrey Robb, M.D.
Eric Strom, M.D.
Christopher Wood, M.D.
Alan Yasko, M.D.

Published by the Department of Scientific Publications-234, The University of Texas M. D. Anderson Cancer Center, 1515 Holcombe Boulevard, Houston, Texas 77030, 713-792-3305.

Made possible in part by a gift from the late Mrs. Harry C. Wiess. Not printed at state expense.

NCI® A Comprehensive Cancer
CCC Center Designated by the
National Cancer Institute