

5  
Dynamic Research  
Adult stem cells could  
one day be used to treat  
damaged tissue.

7  
The Buzz over Stem Cells  
House Call explains the  
difference between embry-  
onic and adult stem cells.

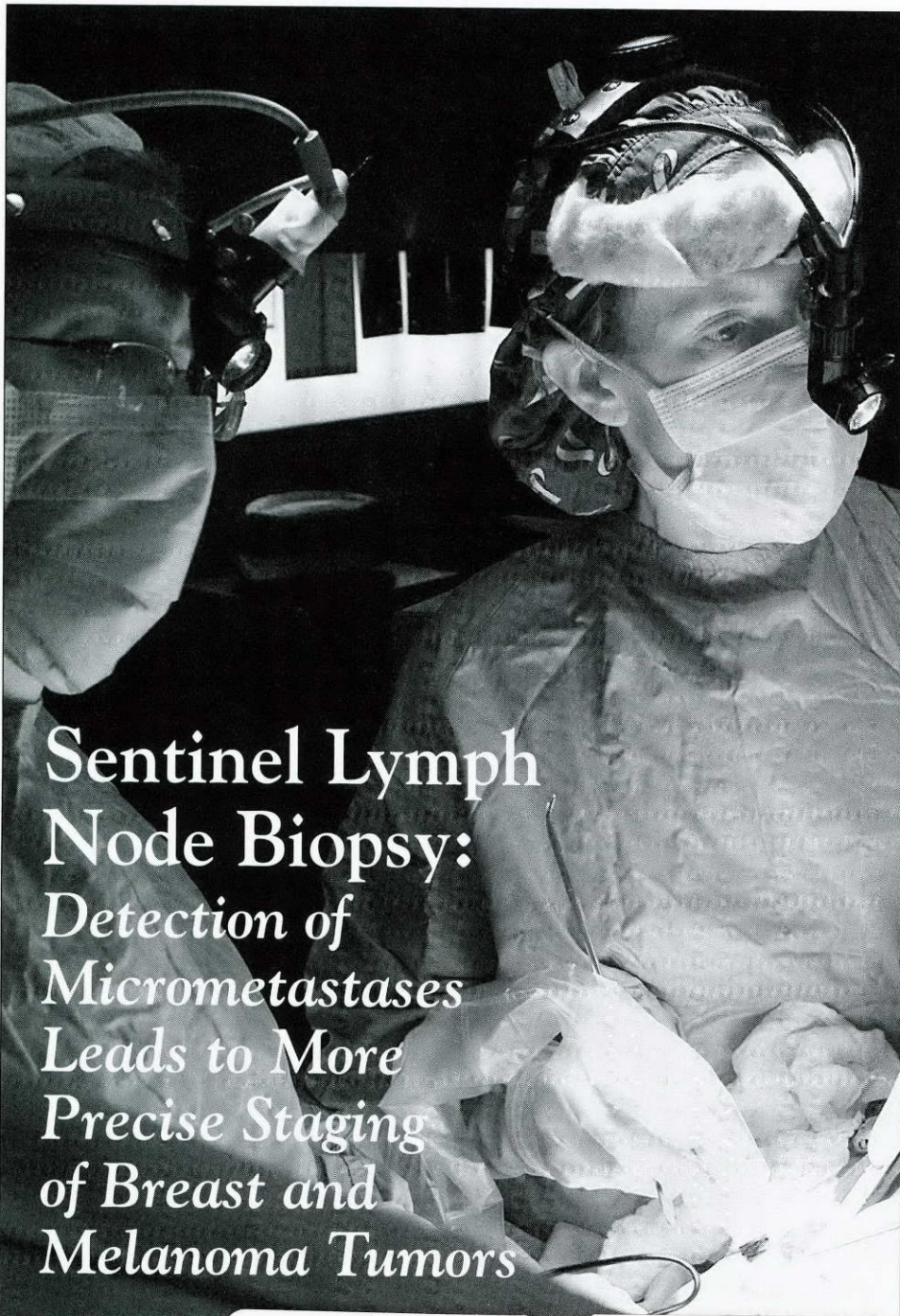
8  
DiaLog  
Directed parathyroid  
surgery is highly successful  
and reduces morbidity.

NON-CIRCULATING

REPORT TO PHYSICIANS

SEPTEMBER 2003 Vol. 48, No. 9

# Oncology



by Katie Prout Matias

**L**ike detectives tracking clues that a suspect leaves behind, surgical oncologists use a technique called sentinel lymph node biopsy to find cancer cells that have escaped the tumor and threaten to infiltrate other parts of the body. The sentinel node, or the first lymph node to which extracellular fluid from a tumor drains, acts as the gateway to the lymphatic system and beyond. Thus, the presence or absence of tumor cells in the sentinel node provides a wealth of information about the nature of a cancer and how best to treat it.

(Continued on next page)

To locate the sentinel lymph node in a patient with breast cancer, **Mary Jennings** (left), an advanced practice nurse in the Department of Surgical Oncology, and **Dr. Kelly Hunt**, an associate professor in the department, watch the digital readout from a gamma probe.

THE UNIVERSITY OF TEXAS  
MD ANDERSON  
CANCER CENTER

# Sentinel Lymph Node Biopsy

(Continued from page 1)

The current standard of care for melanoma and breast cancer, sentinel lymph node biopsy spares patients who have no trace of disease in their sentinel nodes from the sometimes severe complications of having an entire nodal basin removed: chronic swelling, discomfort, infection, and reduced mobility. The procedure also allows for more thorough pathologic analysis and more accurate staging, perhaps even improving survival rates in patients with certain cancers. As researchers at The University of Texas M. D. Anderson Cancer Center work to maximize the benefits of sentinel lymph node biopsy, however, two issues remain unresolved: What is the best way to find and manage micrometastatic disease, and how important are alternative lymphatic drainage patterns?

## Finding the sentinel node

Surgical oncologists hunt for the sentinel lymph node armed with a radioactive tracer and blue dye. The radioactive tracer is used first to illuminate the route of the tumor's drainage. During lymphoscintigraphy, the tracer is injected around the tumor or biopsy site, and a gamma camera captures its final destination.

In an operating room, the surgeons use a hand-held gamma probe to find the "hot spot" or area of high concentration of radiation. This is where the sentinel node, packed full of radioactive tracer, lies. They next inject the bright blue dye around the tumor site and massage it to encourage the dye to migrate quickly to the sentinel node. After a few minutes of massaging, the surgeons cut a small opening in the skin at the hot spot and look for one or more bean-like nodules dyed bright blue.

Once the surgeons have identified any suspicious nodes, they remove them and pass them on to the pathologist. The presence and number of tumor cells in the lymph nodes are strong prognostic factors. "The amount of disease within that lymph node is a very good predictor of the likelihood that a patient will remain cancer free," said Jeffrey Lee, M.D., a professor in the Department of Surgical Oncology.

"Patients with larger amounts of cancer are more likely to suffer a relapse."

## Identifying micrometastatic disease

In the past, when completion dissections were routinely performed on all patients, pathologists would have to scrutinize 15 to 30 lymph nodes, a time-consuming and expensive task, according to Ebrahim Delpassand, M.D., an associate professor in the Department of Nuclear Medicine. Now, they usually inspect one or two sentinel nodes, which allows them to more

meticulously examine each node for micrometastases.

Finding pathology assays that can quickly and accurately identify micrometastasis is now the most important goal for sentinel lymph node biopsy because it is the key to managing tumors, according to Merrick Ross, M.D., a professor in the Department of Surgical Oncology.

In the Sunbelt Melanoma Trial, Drs. Lee and Ross are investigating the use of polymerase chain reaction (PCR) to detect cancer cells at the molecular level. Using PCR, which could be

## Sentinel Lymph Node Biopsy Shows Promise in Eye and Colon Cancers

by Katie Prout Matias

**A**s the use of sentinel lymph node biopsy in melanoma and breast cancer continues to evolve, researchers at The University of Texas M. D. Anderson Cancer Center are finding ways to modify and adapt the procedure for other types of cancer, including conjunctival, eyelid, and colon cancers.

Performing sentinel lymph node biopsy in tumors of the eye requires skill and teamwork because of the unique anatomic considerations in the periocular region. "It requires someone who is familiar with the eye to work closely with someone who is very familiar with doing sentinel lymph node biopsy in the head and neck region. Head and neck sentinel node biopsy is a little different from the rest of the body. It has a higher learning curve," said Bitu Esmaeli, M.D., an associate professor and chief

of the Section of Ophthalmology in the Department of Plastic Surgery at M. D. Anderson and an ophthalmic plastic surgeon. Dr. Esmaeli and Merrick Ross, M.D., a professor in the Department of Surgical Oncology at M. D. Anderson, have adapted sentinel lymph node biopsy for conjunctival and eyelid tumors.

"The problem with the head and neck region is that it is so rich in lymphatics, and the ambiguity of lymphatic drainage patterns is really high," said Dr. Ross. "But in conjunctival melanomas, our experience has been that the lymphatic drainage patterns are actually relatively straightforward; they almost always drain to the parotid region and the upper neck."

Drs. Esmaeli and Ross have also performed sentinel lymph node biopsies for eyelid tumors, including sebaceous cell carcinomas and Merkel cell carcinomas, which can have rates of nodal involvement of 20% to 50%.

Initial concerns that performing a sentinel lymph node biopsy in the eye region might permanently discolor the eye with the blue dye used to locate the sentinel node or cause cataracts or dryness from the radioactive tracer have not materialized. Another issue with the radioactive tracer was how much to inject. Dr. Esmaeli noticed that, because the conjunctiva is a mucous membrane with a contiguous underlying space and the eye is so small, injecting the usual volume of tracer used for sentinel node biopsy in other locations caused the

sensitive enough to detect one melanoma cell among a million normal cells, they are looking in lymph nodes for the presence of genes that are typically expressed in melanoma. "We're hopeful that some of these techniques may help us to identify small amounts of cancer that are not apparent looking under the microscope with our best techniques," said Dr. Lee.

For patients with breast cancer, researchers have not yet identified which markers could be used with PCR. Instead, they are focusing on ways to intraoperatively examine lymph nodes

for micrometastases so that if a positive node is discovered, the surgeons will not have to operate a second time to remove the rest of the nodes. Currently, in examining the nodes of patients with breast cancer, pathologists at M. D. Anderson use touch preparations in which they slice the node, pat the two halves onto slides, and examine the cells that stick to the slides.

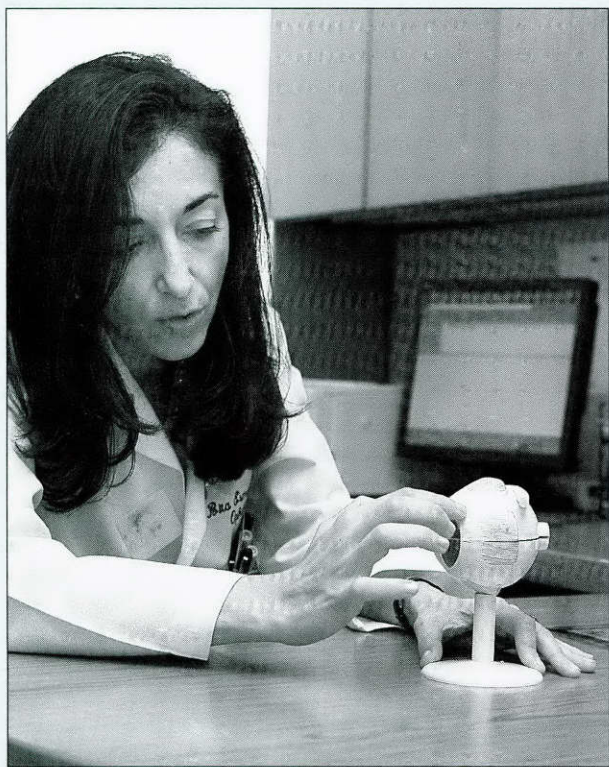The accurate staging made possible by such painstaking pathology allows oncologists to choose the most appropriate therapies. "I think it really helps us to get a little bit closer to identifying the

patients at high risk for metastatic disease so that we can be more careful with our treatments," said Kelly Hunt, M.D., an associate professor in the Department of Surgical Oncology. "Certainly, we help a lot of people with chemotherapy, but there are some people that we're not helping."

### Too much of a good thing?

Using these highly sensitive techniques, pathologists are uncovering more micrometastases than they have in the past. "We found that the more you

*(Continued on page 4)*



**Dr. Bitia Esmaeli**, an associate professor and chief of the Section of Ophthalmology in the Department of Plastic Surgery, uses a model eyeball to demonstrate to patients where she will inject the radioactive tracer and blue dye during sentinel lymph node biopsy.

agent to spread on the surface of the eye and drain to nonspecific nodal basins. By using a smaller needle and decreasing the volume, she was able to identify the sentinel node or nodes successfully.

To illustrate how the use of sentinel lymph node biopsy can affect the treatment of eye tumors, Dr. Esmaeli related the case of a 58-year-old man who had a conjunctival melanoma

removed from the surface of his eye. Ultrasonography and magnetic resonance imaging found no disease in his lymph nodes. In this situation, the standard of care is to wait and see if the melanoma metastasizes, which can occur in as many as 30% of conjunctival melanomas. Instead, the man's local ophthalmologist referred him to M. D. Anderson, where Drs. Esmaeli and Ross performed a sentinel lymph node biopsy and identified three sentinel nodes. One turned out to be histologically positive for metastatic melanoma, and the patient's melanoma was upgraded from stage I to stage III.

"Sentinel node biopsy drastically changed this patient's treatment; instead of just waiting for his

metastatic disease to become clinically obvious, we found his microscopic lymph node metastasis early, and he had neck dissection, radiation therapy, and was enrolled in a phase III trial for systemic interferon," said Dr. Esmaeli. "For aggressive malignancies of the conjunctiva and eyelid, sentinel lymph node biopsy is an important advance because we would otherwise miss

microscopic nodal involvement in these patients."

Sentinel lymph node biopsy has also been modified for more common tumors. In colon cancer, the procedure is used solely for staging purposes, to help the oncologists decide whether to administer chemotherapy. Performing a sentinel lymph node biopsy in place of a complete lymph node dissection in patients with colon cancer does not reduce surgical morbidity because there are no side effects associated with removing the mesenteric lymphatics. Thus, lymphatic mapping is sometimes performed *ex vivo* when there is too much fatty tissue inside the body to see the nodes. In *ex vivo* mapping, the surgeons inject the localization agents, resect the tumor and the lymphatics, and then remove any positive nodes for analysis. While the false-negative rates of sentinel lymph node biopsy are higher in colon cancer than in melanoma or breast cancer, there is hope that the rates will improve with the development of more sensitive pathologic techniques.

As more patients enroll in clinical trials of these experimental sentinel lymph node biopsies, surgical oncologists will continue to perfect the procedure so that staging and even survival benefits may be realized for patients with many different kinds of tumors. ●

**FOR MORE INFORMATION**, contact Dr. Esmaeli at (713) 794-1247 or Dr. Ross at (713) 792-7217.

# Sentinel Lymph Node Biopsy

(Continued from page 3)

look, the more you find. Sometimes we're actually finding just single cells that look like they're probably malignant cells," said Dr. Hunt. "The question is, are those cells just passing through the lymphatic system and would normally be cleared out by the lymphatics, or are they truly an important biologic event that we then need to treat with more surgery or chemotherapy?"


One of the biggest controversies in sentinel lymph node biopsy is whether surgeons should remove all of the nodes when micrometastatic disease is found. To answer this question, researchers are developing prediction models. In a study of 160 patients with breast cancer who had positive sentinel nodes, Dr. Hunt and others found that using additional parameters—such as the size of the metastasis in the lymph node, the presence or absence of lymphovascular invasion in the primary tumor, the number of lymph nodes that were removed, and the size of the primary tumor—they could predict which patients were going to have additional nodal metastases and which were not.

"I think the challenge for sentinel lymph node biopsy is to continue to refine the groups of patients who will most benefit from the technique," said Dr. Lee. "Most important, it will be helpful to identify patients who may not need completion lymph node dissection."

## Which way do they go?

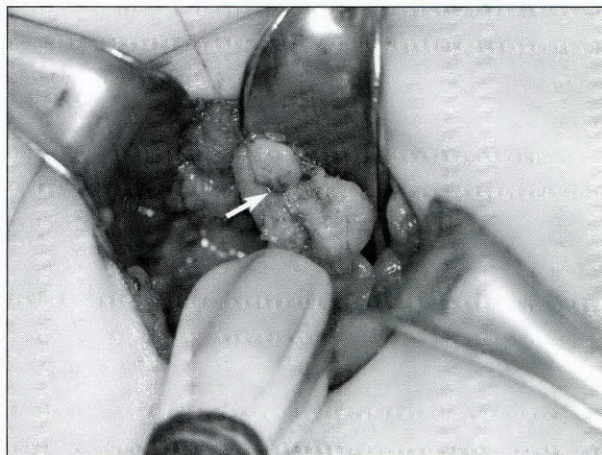
No two lymphatic systems are exactly the same, so it is not always possible to predict clinically or anatomically where a tumor will drain. Furthermore, certain areas of the body, such as the head, neck, and trunk, have ambiguous drainage patterns. In the trunk, for example, about 5% to 10% of tumors migrate to ectopic or interval node groups in addition to the usual inguinal and axillary nodes, said Dr. Ross.

In breast cancers, while most tumors drain to the axilla, there are some that drain to the internal mammary nodes, the supraclavicular nodes, and the intramammary nodes. Even using



**Dr. Robert Andtbacka** (left), a fellow in the Department of Surgical Oncology, and **Dr. Merrick Ross**, a professor in the department, discuss a lymphoscintigram.

At right, the arrow indicates a concentration of blue dye in an axillary lymph node. The gamma probe, bottom, is inserted into the incision to help the surgeons more precisely locate the target node or nodes.



sentinel lymph node biopsy, surgeons sometimes overlook or ignore these unexpected nodal basins. "What we're doing with sentinel node mapping is trying to be very focused. We're trying to be more accurate with our staging system. So why would we want to ignore potential alternative drainage sites?" asked Dr. Hunt.

Drs. Hunt and Delpassand have found that the site of the tracer injection influences where it will drain. Injections to the skin almost never drain to the internal mammary nodes, but injections to the breast parenchyma drain to the internal mammary nodes in about 15% to 20% of patients.

Preoperative chemotherapy for breast cancer can potentially obfuscate drainage patterns because the chemotherapy often

shrinks tumors, leaving scar tissue and fibrosis that make it hard for surgeons to inject a tracer or dye into the tumor. In melanomas, wide local excisions of the trunk, which has an ambiguous drainage pattern to begin with, can throw the drainage off its normal path.

Surgical oncologists at M. D. Anderson see these and other challenges as part of a learning curve to be overcome with practice and knowledge. "I think this is just an amazing opportunity to... look at the anatomy and the drainage of each individual tumor very carefully," said Dr. Hunt. ●

**FOR MORE INFORMATION**, contact Dr. Lee at (713) 792-7218, Dr. Delpassand at (713) 792-7031, Dr. Ross at (713) 792-7217, or Dr. Hunt at (713) 792-7216.

# New Research Promotes a More Dynamic View of Adult Stem Cell Differentiation

## Hematopoietic Stem Cells May One Day Be Used to Repair Tissue Damage Caused by Radiation Therapy or Chemotherapy

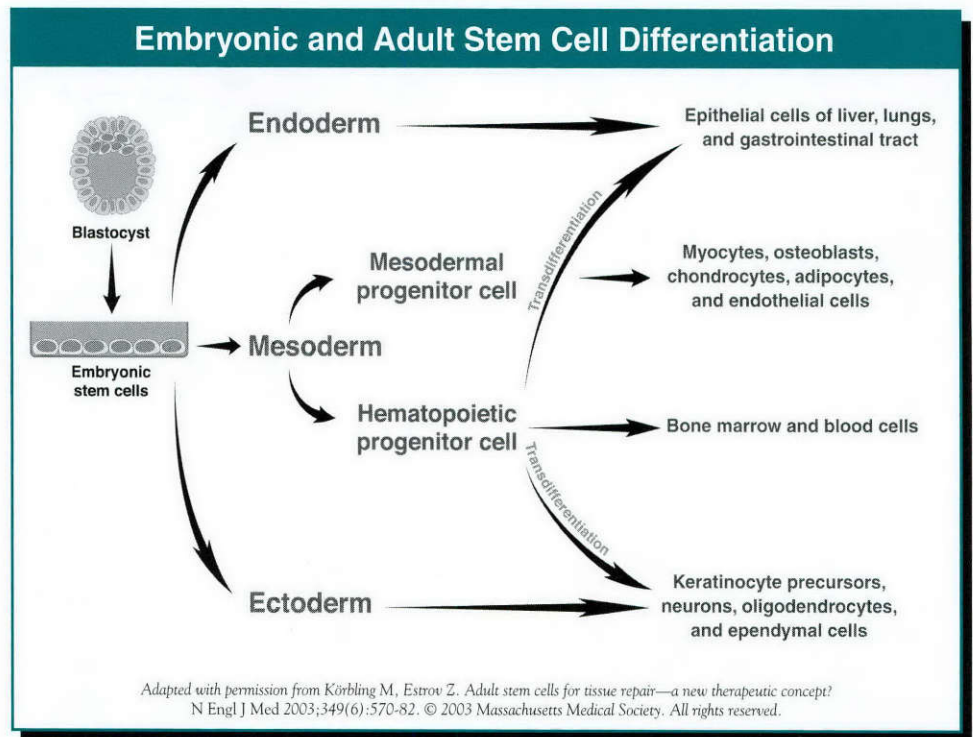
by David Galloway

**T**he classical model of the human cell system has cells traveling on a one-way street: An embryo is conceived, and embryonic stem cells grow into adult cells that form specific parts of the body, carry out their functions, and then die. Once a cell becomes a liver cell, for example, it remains a liver cell for the rest of its life. But recent research suggests a more dynamic picture, with cells constantly dying and being replaced by newly created cells of uncertain origin. It might even be possible for a liver cell to generate brain cells.

"When I grew up, I was taught that neuronal cells were irreplaceable—if you lose them, you've lost them for life," said Zeev Estrov, M.D., a professor in the Department of Bioimmunotherapy at The University of Texas M. D. Anderson Cancer Center. That belief is being challenged as researchers begin to unravel the mysteries of adult stem cells.

"It's so fascinating, if you really think it through—and this is all hypothetical—that our cell system and our body are much more dynamic than what we had thought," said Martin Körbling, M.D., a professor in the Department of Blood and Marrow Transplantation at M. D. Anderson.

In this dynamic model, the body is constantly repairing itself. For example, Dr. Estrov said, "If you walk outside



Embryonic stem cells are capable of differentiating into any of the three germ-layer cells. Adult stem cells were believed to differentiate only along a certain pathway, but some recent studies have suggested that hematopoietic stem cells can cross germ-layer boundaries to form endodermal or ectodermal cells.

today, and you stay out a little bit longer, then you can't even describe what happens in your lungs. You inhale all the smoke and dust and toxins, and the body deals with it very successfully. When there is a failure in the system, you'll be short of breath. It happens because the system has failed. But usually, for most people, the system is successful. There is damage and repair."

Most of this cycle of damage and repair occurs within individual cells. In some cases, however, large numbers of specific cells may be needed to repair tissues. Scientists have known for some time that certain adult stem cells, the hematopoietic progenitor cells, create red blood cells. Drs. Estrov and Körbling have researched using such cells to direct the repair of tissue damage. In a study published in 2002 in the

*New England Journal of Medicine*, they found that circulating stem cells could, as expected, differentiate into mature blood cells, but they could also become hepatocytes and epithelial cells of the skin and gastrointestinal tract.

Other studies have shown potential benefits of adult stem cell treatment in repairing heart muscle damage due to infarction, in regenerating blood vessels to reverse ischemia in lower extremities, and even in repairing spinal cord injuries. Clinical studies are under way to investigate potential treatment strategies, including the repair of tissue damage caused by chemotherapy or radiation therapy by increasing the concentration of stem cells at the site of damage. This can be done either by injecting stem cells directly into the area where they

(Continued on page 6)

# Research Promotes a More Dynamic View of Adult Stem Cells

(Continued from page 5)

are needed or by administering human granulocyte colony-stimulating factor systemically.

The mechanisms of adult stem cell differentiation are not completely understood, but possible explanations for the differentiation of adult stem cells derived from bone marrow or corporeal blood into non-lymphohematopoietic tissue cells include the following:

- In the deterministic model, several types of stem cells circulate, and each distinct type differentiates into a specific kind of tissue.
- In the somatic stem cell model, multipotent adult progenitor cells, primordial equivalents of embryonic stem cells, give rise to circulating, lineage-restricted stem cells.
- In the transdifferentiation model, a stem cell that normally follows a certain differentiation pathway deviates and crosses over to a different lineage.
- In the dedifferentiation and redifferentiation model, a differentiated cell regains stem cell-like properties and generates differentiated cells of another tissue.


Although none of these models has been proven, preclinical data support the transdifferentiation model. It is also possible, however, that more than one model may be at work simultaneously.

Most adult hematopoietic stem cells reside in the bone marrow. Only about 0.1% of the body's stem cells are circulating in the corporeal blood at any given time. These cells circulate to create homeostasis, ensuring that the percentage of stem cells in the marrow remains uniform among the more than 200 bones in the human body. For example, if the bone marrow in a patient's leg is destroyed by radiation therapy, stem cells circulating in the corporeal blood will be delivered to the site of damage until the stem cell concentration in those bones increases



*"...when you understand the mechanisms by which a cell from one tissue can be reprogrammed to become a cell of another tissue, then, in theory, you can take a cancer cell and reprogram it to be noncancerous."*

– Zeev Estrov, M.D.,  
professor, Department of  
Bioimmunotherapy



*"It's so fascinating...that our cell system and our body are much more dynamic than what we had thought."*

– Martin Körbling, M.D., professor,  
Department of Blood and Marrow Transplantation

to the same level found in the rest of the patient's bones.

Both Dr. Estrov and Dr. Körbling said they were inspired by the work of Helen M. Blau, Ph.D., a professor in the Department of Microbiology and Immunology at the Stanford University School of Medicine. In the June 29, 2001, issue of *Cell*, Dr. Blau's article titled "The Evolving Concept of a Stem Cell: Entity or Function?" put forth the hypothesis that a stem cell is defined less by what it is than by what it does. "So [Dr. Blau's argument is that] any cell can acquire the stem cell function under certain conditions," Dr. Körbling said. "Your skin cells can acquire the stem cell function and go back and produce something else. It's a very, very dynamic understanding of the universe of stem cell biology."

One benefit for researchers using adult stem cells rather than embryonic stem cells is the avoidance of controversy. The political, ethical, and religious objections to embryonic stem cell research do not apply to the field of adult stem cells. According to Dr. Körbling, however, adult stem cell research cannot obviate the need for embryonic stem cell research. "An embryonic stem cell can differentiate into all three germ layers—mesoderm, ectoderm, and endoderm," Dr. Körbling said. "This is the most totipotency you can imagine, but it is lost almost

immediately. Whenever those cells are pushed into differentiation, this kind of potential is lost. And then we are into the adult stem cells."

Dr. Estrov agreed. "I think the breakthroughs in terms of understanding the mechanisms of differentiation are most likely to come from embryonic stem cell research," he said.

Dr. Estrov and Dr. Körbling believe that continuing discussions between ethicists and researchers are needed to establish common ground so that the study of embryonic stem cells can continue and people's beliefs and convictions are respected.

And both believe that future research using adult stem cells could open countless doors for scientists, clinicians, and patients.

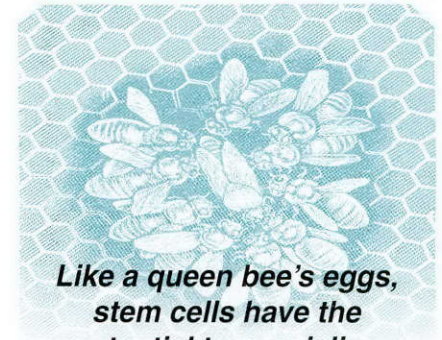
"If you think about the future applications of this, when you understand the mechanisms by which a cell from one tissue can be reprogrammed to become a cell of another tissue, then, in theory, you can take a cancer cell and reprogram it to be noncancerous," Dr. Estrov said. "So it's like every other field of medicine: You start from one field, and then you have implications for many, many other fields. It's never limited." ●

**FOR MORE INFORMATION**, contact Dr. Estrov at (713) 794-1675 or Dr. Körbling at (713) 745-3219.



# Understanding the Buzz over Stem Cells

**A** human stem cell is very much like a queen bee's egg. A beehive must have the right numbers of the right types of bees to survive and produce honey. Although the queen's eggs are all exactly alike, the worker bees treat the honey with special ingredients to control what types of bees develop: workers, drones, guards, or another queen. Therefore, each egg has the potential to become any type of bee in the hive. This same potential exists in stem cells.



**Like a queen bee's eggs, stem cells have the potential to specialize.**

## Embryonic Stem Cells

Embryonic stem cells can become any of the more than 200 cell types in the human body. This unique characteristic gives them tremendous potential as a treatment for many different diseases and conditions, which is why they are the most interesting stem cells to scientists.

Embryonic stem cells have not yet been used to treat humans, but scientists hope to eventually use them to develop replacement cells and tissues for parts of the body that are damaged, diseased, or worn out. Once scientists discover how to control the types of cells that embryonic stem cells become and overcome other obstacles, they will be able to transplant specialized cells derived from embryonic stem cells into patients to treat many conditions, such as Parkinson's disease, diabetes, spinal cord injury, and heart failure.

The use of human embryonic stem cells for research and therapy is controversial, however. Embryonic stem cells used for research typically come from four- to five-day-old embryos, whose development must be terminated to extract the stem cells (30-40 cells). The embryos come from in vitro fertilization clinics, where the eggs of women who are having difficulty becoming pregnant are fertilized in a laboratory. Not all of the fertilized eggs from each woman who is treated at the clinic are implanted into the woman's womb, and some of the "extra" embryos are used in stem cell research. The point is that each healthy embryo has the potential to become a baby.

## Adult Stem Cells

Fortunately, this moral dilemma does not exist with the use of adult stem cells. Unlike embryonic stem cells, adult stem cells are scattered throughout the tissues of the body, and they are far more difficult to isolate and grow in culture than are embryonic stem cells. However, much like embryonic stem cells, adult stem cells are unspecialized cells that can generate specialized cells, such as nerve cells, bone cells, liver cells, and muscle cells. Adult stem cells can proliferate, or replicate themselves, for years and continue to produce differentiated, or specialized, cells as needed. When tissue is damaged, adult stem cells produce cells to replace the damaged ones. Adult stem cells generally produce the cell types of the tissue in which they live. Until recently, they were thought to be able to produce only those cell types, but new evidence shows that at least some adult stem cells can produce the cells of other tissues. For example, adult bone marrow or peripheral blood-derived stem cells can produce heart, skeletal muscle, skin, brain, and lung cells.

Stem cells found in bone marrow have been transplanted from healthy donors to sick patients for more than 40 years to treat many blood disorders and leukemia and lymphoma. In studies of a very limited number of patients, adult stem cells have even been used to treat patients with diabetes or advanced kidney cancer. Recently, researchers at M. D. Anderson Cancer Center discovered that cells derived

from stem cells donated for bone marrow transplants became functioning liver cells. Further testing revealed donor-derived stem cells in the liver, skin, and gut tissue of transplant recipients. This discovery means that stem cells circulating in the blood might be used in treatments to repair many different kinds of tissues or organs.

The potential of stem cell research is as unlimited as that of the stem cells themselves. Knowing the difference between embryonic and adult stem cells, their origins, and their potential uses in medicine will help guide decisions about their research and development. ●

More information about stem cells and stem cell research can be found at the following National Institutes of Health Web sites:

- <http://stemcells.nih.gov/infoCenter/stemCellBasics.asp> and
- <http://www.nih.gov/news/stemcell/>.

For more information, contact your physician or contact the M. D. Anderson Information Line:

- ☎ (800) 392-1611 within the United States, or
- ☎ (713) 792-6161 in Houston and outside the United States.

September 2003


©2003 The University of Texas  
M. D. Anderson Cancer Center

## DiaLog

### Directed Parathyroid Surgery

**Jeffrey E. Lee, M.D.**  
Professor, Department of  
Surgical Oncology

Directed operations such as sentinel lymph node mapping can potentially improve the effectiveness of staging and therapy and at the same time minimize morbidity.



Similarly, patients with primary hyperparathyroidism can undergo a directed operation with high success and low morbidity when a combination of preoperative sestamibi imaging and the rapid intraoperative assay for parathyroid hormone (rPTH) is used. This approach has become an important component of a minimally invasive parathyroidectomy that utilizes small incisions and local anesthesia and has been applied to the treatment of patients undergoing initial and reoperative parathyroid surgery.

Technetium (Tc)-99m sestamibi imaging has become a standard part of the preoperative evaluation of patients with hyperparathyroidism. In approximately 80% of patients, the technique successfully localizes a parathyroid adenoma, which allows for a directed operation. In the 20% of patients in whom localization is unsuccessful, a repeat study following short-term thyroid suppression with liothyronine is safe and can result in successful localization.

At M. D. Anderson Cancer Center, we employ an rPTH assay that delivers results within 15 minutes of specimen collection. Baseline samples are compared

with samples taken five and 10 minutes postexcision. A 50% drop in the rPTH value from baseline is indicative of clinical cure in patients with primary hyperparathyroidism. A lesser drop in the rPTH level calls for bilateral neck exploration to determine the presence or absence of multigland disease. In patients with multiple endocrine neoplasia type 1, who typically have multigland disease and are at risk for recurrent hyperparathyroidism, it is reasonable to target an 80% fall in the rPTH value; this rate also works well for patients with secondary hyperparathyroidism or parathyroid hyperplasia. In these patients, it is also desirable to have the rPTH level fall to within the normal range.

While not essential to the routine management of patients with primary hyperparathyroidism, intraoperative gamma probe localization can be used. The gamma probe may be particularly helpful during reoperative surgical procedures.

We have found that preoperative sestamibi scintigraphy, combined with the rPTH assay, allows for a successful directed parathyroidectomy in most patients and that this minimally invasive approach is well tolerated. Patients appreciate this approach because, most of the time, it allows them to avoid the side effects of general anesthesia. Their recovery is faster and more comfortable, and surgery can usually be performed as an outpatient procedure. As an endocrine surgeon, I find it satisfying to be able to perform a directed operation and be confident before leaving the operating room that the patient's hyperparathyroidism has been cured.

# OncoLog

The University of Texas  
M. D. Anderson Cancer Center

**President**  
John Mendelsohn, M.D.

**Executive Vice President  
and Chief Academic Officer**  
Margaret L. Kripke, Ph.D.

**Vice President for Educational Programs**  
Stephen P. Tomasic, Ph.D.

**Director, Department of  
Scientific Publications**  
Walter J. Pagel

**Managing Editor**  
Dawn Chalaire

**Contributing Editors**  
David Galloway  
Katie Prout Matias  
Chris Yeager

**Design**  
The Very Idea®

**Photography**  
Jim Lemoine  
Barry Smith

**Editorial Board**  
Rena Sellin, M.D., *Chair*  
Therese Bevers, M.D.  
Thomas Burke, M.D.  
David Callender, M.D.  
Ka Wah Chan, M.D.  
Steven Curley, M.D.  
Eduardo Diaz, Jr., M.D.  
Larry Driver, M.D.  
Frank Fossella, M.D.  
Lewis Foxhall, M.D.  
Robert Gagel, M.D.  
Sergio Giral, M.D.  
Martyn Howgill  
Jeffrey Lee, M.D.  
Charles Levenback, M.D.  
Moshe Maor, M.D.  
Shreyaskumar Patel, M.D.  
Geoffrey Robb, M.D.  
Eric Strom, M.D.  
Christopher Wood, M.D.  
Alan Yasko, M.D.

Published by the Department of Scientific  
Publications-234, The University of Texas  
M. D. Anderson Cancer Center, 1515 Holcombe  
Boulevard, Houston, Texas 77030, 713-792-3305.

Made possible in part by a gift from the late  
Mrs. Harry C. Wiess. Not printed at state expense.



A Comprehensive Cancer  
Center Designated by the  
National Cancer Institute